

Original article

A histopathological study of 35 cases of liver abscess in adults autopsy

¹Ujwal K. Rathod ,²Millind Patil , ³Riya Rathod ,⁴ Prashant Kumavat ,⁵Ganesh Kshirsagar, ⁶Nikhil Majethia

1. Assistant Professor, M.D.Path. Department of Pathology, LTMMC &GH,Sion,Mumbai

2.Associate Professor, Department of Pathology, LTMMC &GH, Sion ,Mumbai

3. Medical officer , Mrs.Meenatai Thakare maternity Home Chunabhatti , Mumabi

4.Assistant Professor, Department of Pathology, LTMMC &GH,Sion,Mumbai

5.Assistant Professor, Department of Pathology, LTMMC &GH,Sion,Mumbai

6. Assistant Professor, Department of Pathology,JJ Hospital, Byculla, Mumabi

Corresponding author : Ujwal K. Rathod

Abstract

It is a known fact that silent liver diseases are common amongst apparently healthy individuals and are sometimes diagnosed only at autopsy. Liver abscess is not an uncommon disease entity . In present study liver abscesses were divided into two groups: the pyogenic (n = 19 ,54.3%) and amoebic group (n = 16 , 45.7%), which were analyzed for differences in clinical and laboratory findings. Elderly were more commonly affected in pyogenic liver abscess while in amoebic abscess, involved middle aged adults followed by young adults. Males predominated the study with a male: female ratio of 6.2: 1. Amoebic liver abscess, most of the abscess were solitary and found in the right lobe of the liver. The study was conducted only on specimens collected from the mortuary and may not reflect the actual pattern of liver diseases in the local population.

Key words: Pyogenic Liver Abscess and Amoebic Liver Abscess.

Introduction:

Liver abscesses have been recognized for centuries and in 1883 amoebae were first described as a cause of liver abscesses. Despite a refinement in diagnostic and therapeutic modalities since then, liver abscess remains a serious condition with a high morbidity and mortality rate.^{1,2} Worldwide, approximately 40 - 50 million people are infected annually with amoebic abscesses, with the majority of infections occurring in developing countries.^{1,2} In endemic areas, the prevalence of infection is higher than 10% and has been reported to be as high as 55% in certain areas. India has 2nd highest incidence of liver abscess in the world.³ Amoebic liver abscesses, most common extraintestinal manifestation of *Entamoeba histolytica* infection . Hepatic involvement is encountered in 3 to 9% of the cases of intestinal amoebiasis.^{4,5,6} Pyogenic is still a serious illness and diagnostic challenge. Pyogenic abscesses of the liver often occurs secondary to infections of the adjacent tissues or biliary or intestinal tracts or hematogenous seeding and are associated with a mortality rate of 20% - 60%, even with appropriate medical-surgical management ⁷. The commonest etiological agents are E.coli and other coliforms, but anaerobes are reported with increasing frequency. So identification of risk factors and early diagnosis are the key issues for effective interventions. Information on liver abscess is very limited from this part of the country. Keeping all these views in mind, the present study was conducted with the following objectives:

Objectives:

1. To study prevalence and etiological factor of various liver abscess in adults autopsy.
2. To study liver abscess in adults in relation to clinical presentations , age and sex .

3. To correlate gross morphological appearances with histopathological features.
4. To study liver abscess in adults in relation to liver function test (LFT) and cause of death with complications.

Material and methods:

The present study was based on autopsy material. This was a descriptive cross sectional retrospective and prospective study carried out from period January 2004 to December 2013 at tertiary care hospital . All the adult autopsies during this ten years period were screened for liver abscess. Details of clinical history, examination and results of various investigative procedures with particular reference to liver function tests were obtained from hospital records whenever available. Standard routine procedure were used for fixation, embedding and sectioning. All sections were stained with Hematoxylin and Eosin. In selected cases special stains like PAS was also performed.

Observation and results:

During the present study period out of the 35 cases , 19 (54.3%) were of pyogenic origin and 16 (45.7%) patients were of amoebic origin. However in this study no organism could be isolated in case pyogenic liver abscess. Etiology of pyogenic liver abscess (n=19) in present study was; ascending biliary cholangitis (42.1%), chronic pyelonephritis (26.3%), perforative peritonitis (15.8%) and bronchopneumonia (15.8%).

Clinically cases presented with fever (100%), abdominal pain (97.1%), hepatomegaly (74.3%) and Jaundice (25.7%) (Fig.1.). Pain in right upper quadrant of abdomen as the commonest presenting feature in our study. Other clinical features noted were abdominal distention (42.9%) which most commonly has seen in amoebic liver abscess. In present study (Fig.2.) elderly were more commonly affected in pyogenic liver abscess while in amoebic abscess middle aged adults were involved followed by young adults. Male predominated the study with Male: Female ratio of 6.2:1(Fig.3).

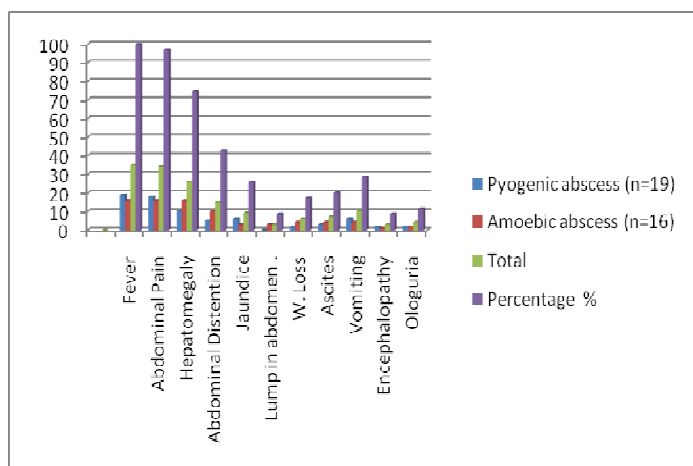


Figure 1 : Clinical features of Pyogenic and Amoebic liver abscess.

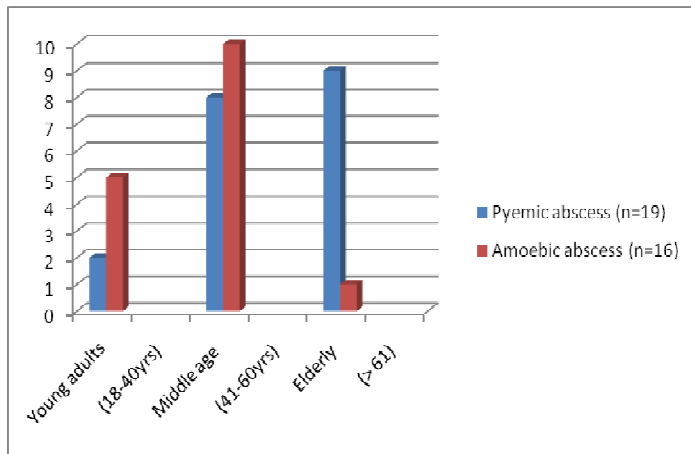


Figure.2 : Age distribution of Pyogenic and Amoebic liver abscess.

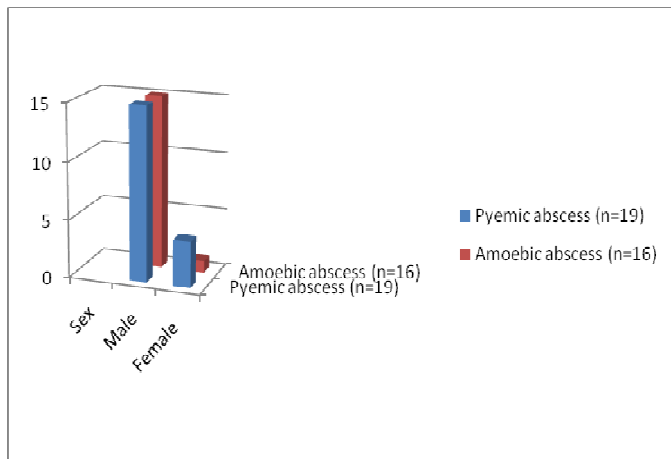


Figure 3 : Sex distribution of Pyogenic and Amoebic liver abscess.

In present study of all patients with pyogenic liver abscess had multiple abscesses. Microscopically composed of mostly neutrophils surrounded by fibrosis (Fig.4 & 5).

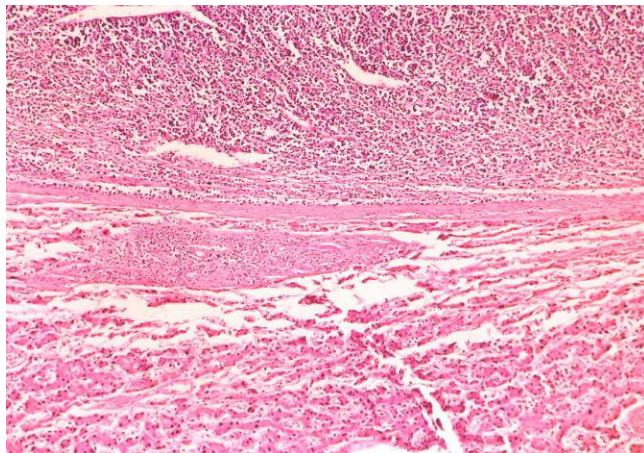


Figure 4. Microscopy features of Pyogenic liver abscess (H. & E. 100x).

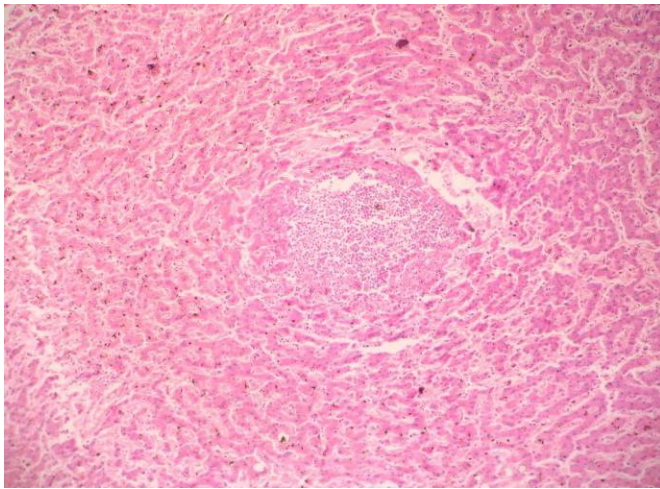


Figure 5. Pyogenic micro liver abscess (H.& E.100x).

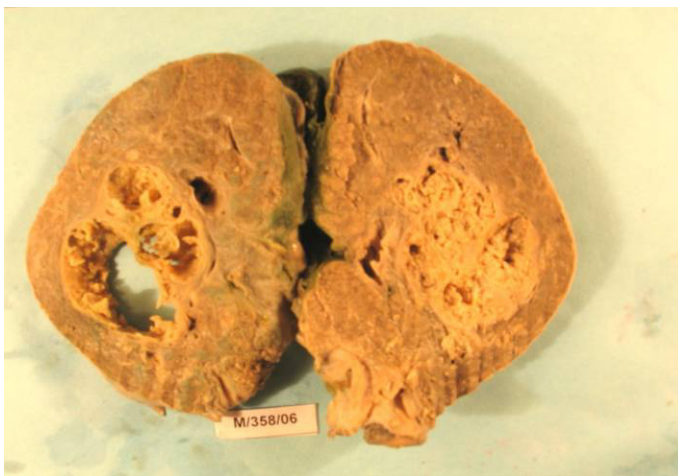

Figure 6: Gross-Solitary Amoebic liver abscess.



Figure 7 : Gross-Multiple Amoebic liver abscess.

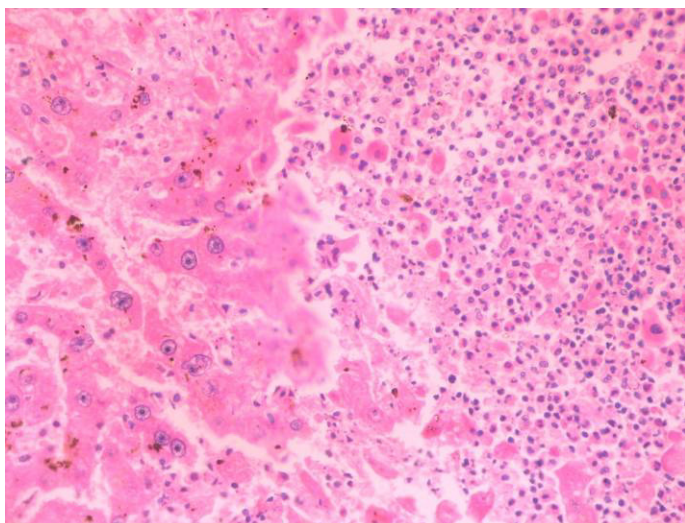


Figure 8. Microscopy features of Amoebic liver abscess with trophozoites (H.& E.100x).

In present study amoebic abscess were classical large solitary abscess ranged from 1cm to 12 cm in dimensions with shaggy necrotic material (Anchovy Sauce) and irregular fibrous wall and found in the right lobe of the liver. On gross examination 12 (75%) were solitary (Fig. 6) and 4 (25%) were multiple (Fig. 7). Histologically lesion consisted of granular and eosinophilic necrosis with nuclear debris (Fig.8). We could identify amoebae in 7 cases (43.75 %) on histology (Fig. 8). Only 5 (31.25 %) cases had amoebic intestinal amoebic ulcers. Liver function test shows mild to moderate increase in bilirubin levels, transaminase and alkaline phosphatases.

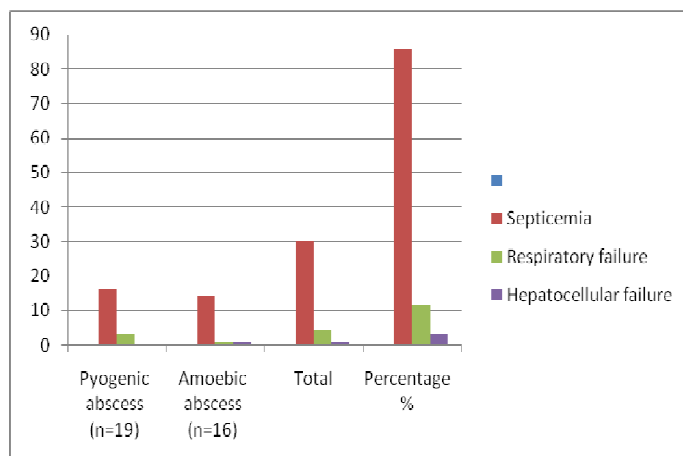


Figure 9 : Distribution of cases according cause of death of Pyogenic and Amoebic liver abscess.

The commonest cause of death were septicemia in present study (Fig.9). Seven (20.00%) patients with amoebic liver abscess had complications like rupture into peritoneal cavity (5) with generalized peritonitis and pleural effusion (2).

Discussion:

Total 35 cases of liver abscess were found after screening all the adult autopsies during this ten years period. Out of the 35 cases, 19 (54.3%) were of pyogenic origin and 16 (45.7%) patients were of amoebic origin. Study done by Rubinson et al.⁸ who found 5 cases of amoebic and 12 cases of

pyogenic liver abscess in a series of 17 cases. A very low percentage of amoebic liver abscess were reported in few other studies done in other parts of the globe.^{9, 10} However in contrast to our finding Singh and his co-workers,¹¹ amoebic liver abscess were encountered more frequently (58%) compared to Pyogenic (23%). Similar finding of high prevalence of amoebic liver abscess in India was revealed by various authors.^{12, 13}

Present study patients presented with fever (100%), abdominal pain (97.1%), hepatomegaly (74.3%) abdominal distention (42.9%) and Jaundice (25.7%) which were also observed by other authors.^{12,13,14, 15} According to Wilmot and Hennessy,¹⁶ jaundice occurs in less than one percent of the cases and is usually obstructive in nature. Adams and Maergraith¹⁷ are of the opinion that jaundice never occurs in amoebic liver abscess.

In present study middle aged (41-60yrs) adults were more commonly affected. In the pyogenic group, the majority of patients were more than 60 years old, while in the amoebic group, most patients were between 41 and 60 years old followed by young adults (18-40yrs). However in contrast to our finding Brandt et al² has reported that it affects all age group except children with peak incidence in 3rd and 4th decade.

Male predominates in present study with Male: Female ratio of 6.2:1. Amoebic abscess revealed that 15 (93.8%) were males and it coincide with the fact that it is common in males as reported in literature.^{18, 22} Farther Oschner and De Bakey's¹⁸ in their review of 642 cases has conceded that M.F. ratio was 16 :1 and this is attributed to endocrine hormonal effects.

Multiple abscess formation was more common in the pyogenic group (100%), while a single abscess was more common in the amoebic group (75%) predominant involvement of right lobe was in conformity with other studies,^{18,19} where as multiple abscess were more common according to Clark et al²⁰, Craig²¹ and Keans et al.²² We could identify amoebae in 7 cases (43.75 %) on histology. Amoebae are intensely PAS positive due to the presence of glycogen in cytoplasm. Incidence of detection of amoebae on histology varies widely in different series like Brand et al² (76.1%) Oschner and De Bakey's¹⁸ (17.4%). Intra-peritoneal rupture^{2, 23, 24} is very serious and most complications of amoebic liver abscesses. In amoebic liver abscess, we observed 5 cases of rupture into peritoneal cavity with generalized peritonitis and 2 cases of pleural effusion^{24, 25, 26}.

Conclusion:

Autopsy study is a good stepping stone towards achieving good morphological accuracy. In pyogenic and amoebic liver abscesses, continue to be an important cause of morbidity and mortality in tropical countries. There was no significant difference clinically and on routine laboratory investigations between pyogenic and the amoebic liver abscess group. Pyogenic and amoebic have many features are common and diagnosis is often delayed due to vague clinical symptoms resulting in adverse outcome. Male predominates in both amoebic and pyogenic liver abscess. Elderly were more commonly affected in pyogenic liver abscess while in amoebic abscess middle aged adults were involved followed by young adults. Pain abdomen, particularly right upper quadrant as the commonest presenting feature of liver abscess along with fever and hepatomegaly. Early diagnosis and prompt interventions improve the survival and outcome of the disease.

References:

1. Bhatti A, Ali F, Satti S, Satti T. Clinical & pathological comparison of Pyogenic and Amoebic Liver abscess *Advances in Infectious Diseases* 2014;4:77-123.
2. Brandt H, Tamayo RP: Pathology of Human Amebiasis. *Human Pathology* Vol. 1, No.3 : 351-381, 1970.
3. Channanna C, Rehman FU, Choudhuri B, Patil A. A clinical study, diagnosis and Management of Liver Abscess at VIMS, Bellary. *Journal of Evidence Based Medicine and Health Care* 2014; 1:668-85.
4. Perez JY Jr. Amoebic liver abscess: Revisited. *Philip J Gastroenterol* 2006;2:11-3.
5. Secto RK, Rockey DC. Pyogenic and amoebic liver abscess, changes etiology *Median*, 1996; 75: 99-113.
6. Nigam P, Gupta AK, Kappor, K.K. Sharan GR, Goya BM, Joshi LD Cholestasis in amoebic liver abscess. *GVT* 1985 26-140-145.
7. Malik AA, Bari SU, Rouf KA, Wani KA. Pyogenic liver abscess: Changing patterns in approach *World J Gastrointest Surg.* 2010 ; 2: 395-401.
8. Rubinson, HA, Isikoff, M.B. and Hill, M.C. Diagnostic imaging of hepatic abscess; a retrospective analysis. *A. TR.*, 1980; 135:735.
9. Mohsen AH, Green ST, Read RC, McKendrick MW. Liver abscess in adults: Ten years experience in a UK centre. *QJM.* 2002;95:797-802.

10. Abbas MT, Khan FY, Muhsin SA, Dehwe BA, Abukamar M, Elzouki AN., Epidemiology, Clinical Features and Outcome of Liver Abscess: A single Reference Center Experience in Qatar . Oman Med J. 2014; 29: 260-63.
11. Singh S, Chaudhary P, Saxena N, Khandelwal S, Poddar DD, Biswal UC. Treatment of liver abscess: prospective randomized comparison of catheter drainage and needle aspiration. Ann Gastroenterol. 2013; 26: 332-39.
12. Jha AK, Das A, Chowdhury F, Biswas MR, Prasad SK, Chattopadhyay S. , Clinicopathological study and management of liver abscess in a tertiary care center. J , Nat Sc Biol Med 2015; 6:71-5
13. Ghosh S, Sharma S, Gadpoyle A K, Gupta H K, Mahajan R K, Sahoo R, et al. , Clinical, Laboratory, and Management Profile in Patients of Liver Abscess from Northern India. Journal of Tropical Medicine 2014 Article ID 142382. Available from: <http://dx.doi.org/10.1155/2014/142382>
14. Hathila TN, Patel CJ, Rupani MP. A Cross-Sectional Study of Clinical Features and Management of Liver Abscesses in a Tertiary Care Hospital, Ahmedabad, Gujarat., National Journal of Medical Research 2014; 4: 249-52
15. Mukhopadhyay M, Saha AK, Sarkar A, Mukherjee S. Amoebic liver abscess: presentation and complication. Indian J. Surg. 2010; 72: 37-41.
16. Wilmot, AJ. Clinical amoebiasis. Philadelphia, Davis, 1962, p.102.
17. Adams, A.R.D. and Maergraith, B.G. Amoebiasis, in clinical tropical diseases. 3rd ed Oxford, Blackwell, 1964, p.3.
18. Oschener A, Debakey M : Amebic hepatic and hepatic abscess. Surgery 13: 460- 493, 612-649, 1943.
19. Chatgidakis CB: The pathology of hepatic amoebiasis as seen on the Witwatersrand. S. , A. J. Clin. Sc 4, 230-245, 1953.
20. Clark HC : The distribution and complications of amoebic lesions found in 186 post mortem examination. Am. J. Trop. Med, 5 : 157-171, 1925.
21. Craig CF: The etiology, diagnosis and treatment of Amoebiasis. The Williams and Wilkins Co. Baltimore, 1994.
22. Kean BH, Gilmore HR, Van Stone WW: Fatal amoebiasis report of 148 fatal case from the Armed Forces Institute of Pathology Ann. Int. Med. 44:931-943, 1956.
23. Singha, H.S.K. Spontaneous intra-peritoneal rupture of solitary (amoebic) liver abscess. Br. J. Surg., 1959; 47:198.
24. Vakil, B.J., Metha, AJ. and Desai, H.N. A typical manifestation of amoebic abscess of livers. J. Trop. Med. Hyg., 1970; 73:63.
25. Young, A.E. The clinical presentation of pyogenic liver abscess. Br. J. Surg., 1976; 65:216.
26. Rhode, P.C., Prieto, O. and Riveros, O. Thoracic complications of amoebic liver abscess. Br. J. Dis. Chest, 1979; 75:302.